

**REVISED**

4:04 pm, Sep 30, 2016

---

This erosion often causes not only esthetic damage but also serious functional problems for many patients.

---

# Repairing Dental Erosion with Minimal-Preparation Dentistry

## Validation of Biological and Functional Esthetics in a Full-Mouth Rehabilitation

Cyril Gaillard, DDS  
 Florin Cofar, DDS  
 Ioana Popp, CDT  
 Jérôme Bellamy, CDT  
 Christophe Hue, CDT

### Abstract

Dental erosion is being seen more and more frequently in dental offices today. Its treatment must be biological, esthetic, and functional. The creation of a treatment plan is critical to therapeutic success. First, it is necessary to determine a new mandibular position, then to redesign the esthetics. Next, the occlusal concept and the new smile must be tested using a mock-up. This allows the validation of function and esthetics so that the dental tissues can be prepared only minimally—or not at all—and maximum enamel is preserved to guarantee the quality of bonding. Finally, digital dentistry enables us to more precisely copy the shapes of mock-ups and therefore the occlusal concept.

**Key Words:** digital dentistry, full-mouth rehabilitation, adhesive dentistry, worn teeth



### Learning Objectives

After reading this article, the participant should be able to:

1. Follow a conservative, systematic protocol for correcting dental erosion.
2. Understand the three treatment components needed to treat dental erosion.
3. Appreciate a predictable method for opening a person's vertical dimension of occlusion.

## Introduction

The prevalence of patients with severe dental wear has increased over the past few years.<sup>1,2</sup> This erosion often causes not only esthetic damage but also serious functional problems for many patients.<sup>3</sup> The etiology can be either mechanical (bruxism) or chemical (acid from ingesting soft drinks or from gastroesophageal reflux). Adhesive dentistry enables us to treat these patients with a very low biological impact by avoiding dental mutilation, especially if we manage to keep the maximum amount of enamel on the tooth, which greatly increases the quality and longevity of the bonding.

The goals of a full-mouth treatment must be to:

- be biological, not iatrogenic, destroying as little natural dentition as possible, with periodontics and occlusion (muscular and articular) also being taken into account
- maintain long-term health and ease of hygiene
- reestablish effective function (mastication) as well as create esthetics that please the patient.

This article presents the rehabilitation of a patient with severe dental erosion, integrating the concept of minimally invasive dentistry with adhesive dentistry and, most importantly, functional dentistry, by knowing the patient's precise occlusal concept and mandibular position.

## Case Presentation

### Examination and Findings

A 40-year-old male patient came to the office for his annual check-up (Fig 1). During initial examination, we brought up his severe dental wear and the fact that it would worsen further due to the absence of enamel on the occlusal surfaces (Figs 2 & 3).

The extraoral exam revealed a largely reduced lower facial zone. The intraoral exam showed significant dental erosion but also extremely developed exostoses on the maxillary and mandible, consequences of very strong occlusal pressure (Figs 4a-5). Exostoses and tori are not necessarily the result of occlusal pressure and can sometimes be solely genetic in nature, but with this patient the cause appears to have been occlusal pressure. We also noted the presence of crowns at teeth #26 and #16, and amalgams on the molars.

The patient stated that he had neither muscle spasms nor articular pain but did have increasing discomfort during mastication and constantly tried to find a comfortable mandible position (he was unable to do so because of faulty proprioceptive feedback due to the severe tooth erosion).

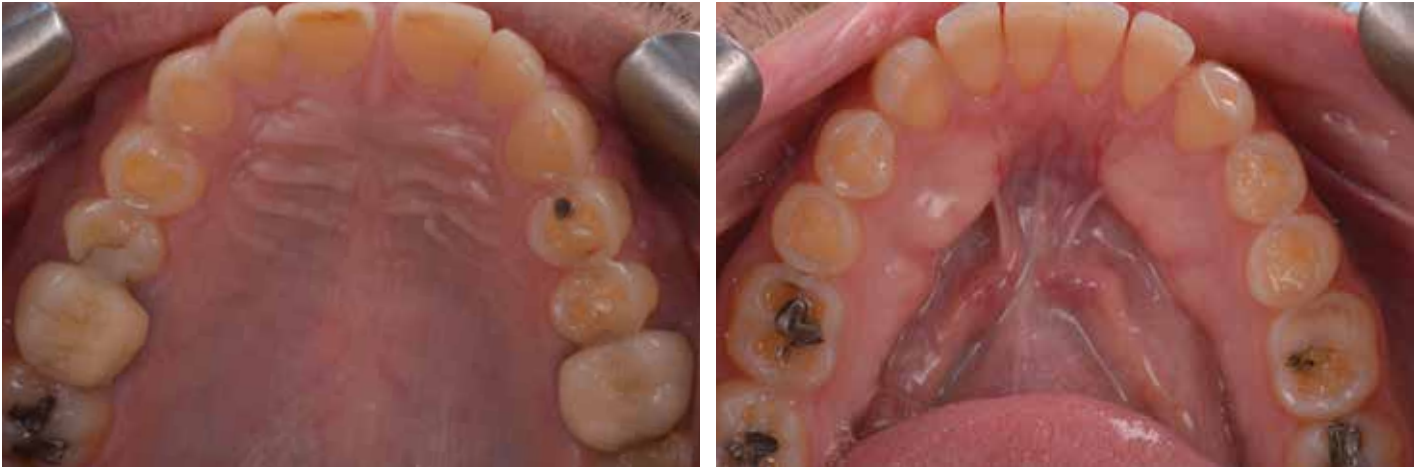

Figure 1: Initial full-face image.

---

The extraoral exam revealed a largely reduced lower facial zone.

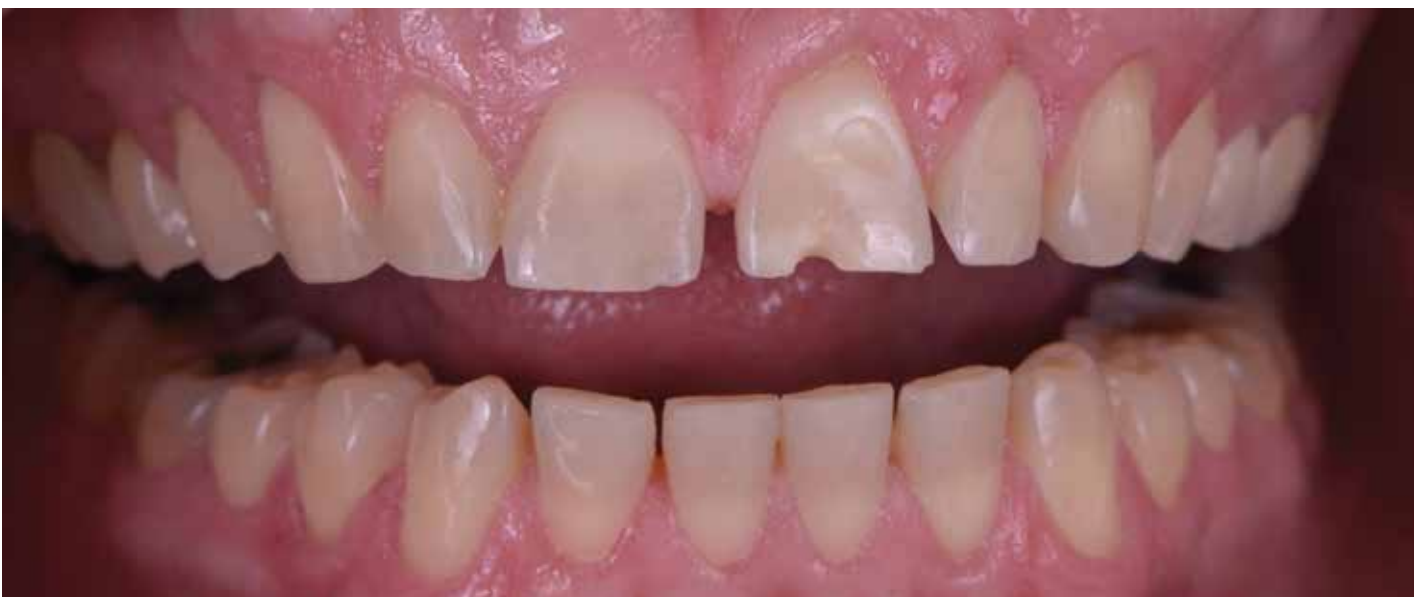---



**Figures 2 & 3:** Initial upper and lower occlusal views showing severe erosion.



**Figures 4a & 4b:** Study models showing the severe wear.



**Figure 5:** Initial intraoral image.

## Treatment Plan

In creating a treatment plan, we followed these steps:

- Talk with the patient to learn his wishes, desires, and possible limitations in terms of treatment.
  - Seek the appropriate mandibular position during occlusal planning to determine how much dental tissue will have to be destroyed.
  - Utilize digital tools in esthetic planning
- Treatment would proceed as follows:
- Clean all the teeth.
  - Complete a mock-up (excluding vestibular faces of ##14-24).
  - Complete a shell mock-up on the vestibular faces of ##14-24.
  - Leave the first mock-up in the patient's mouth for two months to validate the new occlusion.
  - Utilize computer-aided design/computer-aided manufacturing (CAD/CAM) technology to create the definitive prosthesis, integrating the concept of minimally invasive dentistry.<sup>4,6</sup>

## Defining a New Occlusion

### Clinical Phase

A transcutaneous electrical nerve stimulation (TENS) session was scheduled to determine the new occlusion.<sup>7,8</sup> Because the patient's vertical dimension of occlusion (VDO) was deficient, it was necessary to increase it to reconstruct the teeth, not only vertically but also anterior-posteriorly and transversally. It also was necessary to disrupt the patient's faulty proprioception so that the muscles could return to their original, relaxed position. TENS relaxes the muscles and rids them of built-up lactic acid while introducing oxygen and adenosine triphosphate (ATP), thus interrupting the former anaerobic cycle and recreating an aerobic cycle.<sup>9</sup>

The TENS unit [need brand name and mfg. info for the TENS device] was applied to the patient's cranial nerves V, VII, and XI for one hour to relax the paracervical muscles and muscles of mastication. The new occlusion was recorded vertically, anterior-posteriorly, and transversally with a K7 evaluation system (Myotronics; Kent, WA). This system comprises two parts: electromyography to evaluate muscle activity and jaw tracking to see the precise position of the mandible at any given moment.

To record the patient's bite, a magnet was placed on the buccal surface of the lower incisors and we registered the physiologic movement of the jaw including the rest position, the habitual occlusion, and the trajectory of opening and closing.

We determined the new VDO in function of the trajectory of opening and closing and in function of the rest position and the wear of the teeth. To determine the new occlusion we visualized on a software-generated graph the resting position of the patient's mandible after one hour of relaxation with the TENS unit. This position was stable. Starting from this position, when the TENS sends an electrical pulse that contracts the muscles and we can see on the computer screen a line that corresponds to the beginning of the patient's closure. We know that the new occlusion must be found along this trajectory because this trajectory corresponds to the most natural muscular contraction possible. The brain does not intervene to correct this trajectory as it could if there were interferences. So for the occlusion we want to be on the trajectory at approximately 2 mm above the point representing the mandible at rest to create free space. Once the recording was done, we confirmed the position of the temporomandibular joints with a cone beam computed tomograph. For the bite recording, we asked the patient to sit, back straight, eyes closed; he opened his mouth and we injected the silicone without touching him, then guided him into the chosen position using the screen and jaw tracking. Bite registration (Fig 6) was done using Regidur (Bisco France; Lançon-Provence, France) and polyvinyl siloxane (PVS) impressions were taken, then given to the laboratory to create plaster models and a wax-up.

### Laboratory Phase

Plaster models (FujiRock EP, GC, Tokyo, Japan) were made from the PVS impressions in the laboratory, which served as a base for the creation of a maxillary and mandibular wax-up integrating esthetic (incisal edge) and function (palatal and occlusal surfaces). The technician created the wax-up with GEO Snow White L wax (Renfert; Hilzingen, Germany), integrating the occlusal surfaces of the premolars and molars as well as the palatal and lingual surfaces of the incisors and canines, and a lengthening of the incisal edge. Silicone was used on the wax-up to produce a template for the intraoral mock-up (Fig 7).

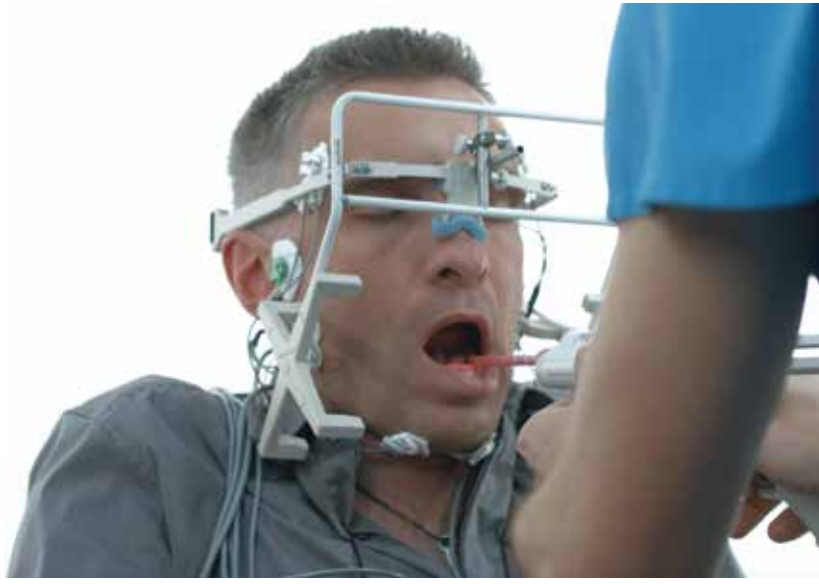## Performing the Mock-Up

Before performing the mock-up, the teeth were cleaned and spots were etched on the surfaces with phosphoric acid, then the teeth were rinsed and dried. The teeth were not prepared in any way. The resin was injected into the maxillary silicone key and the key was pressed onto the maxillary arch. Once the resin had set, the key was gently removed, the excess was eliminated with dental tweezers, and the surfaces were polished. The same process was followed with the mandibular silicone key.

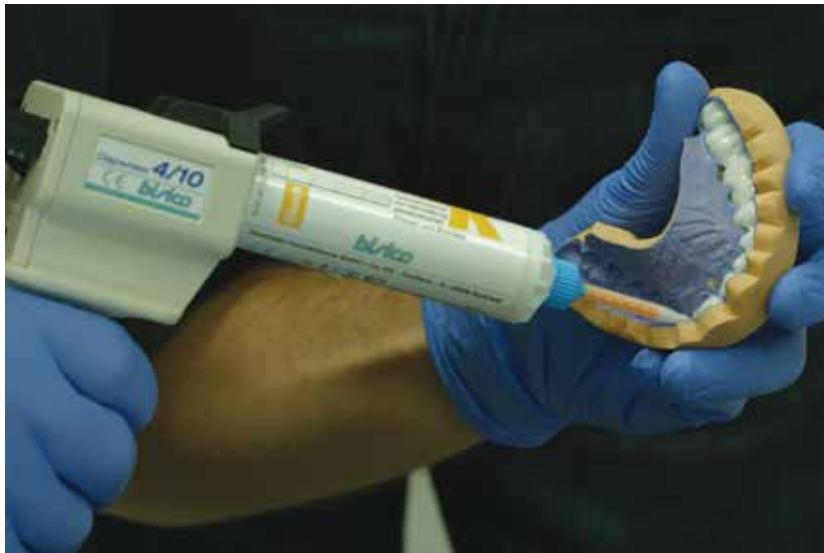### Testing the Occlusion

Once the mock-up had been placed in the patient's mouth (Fig 8), it was necessary to test the new occlusion and adjust if needed. Another one-hour TENS session was conducted so that the facial muscles could once again relax into their proper position newly supported by the mock-up.

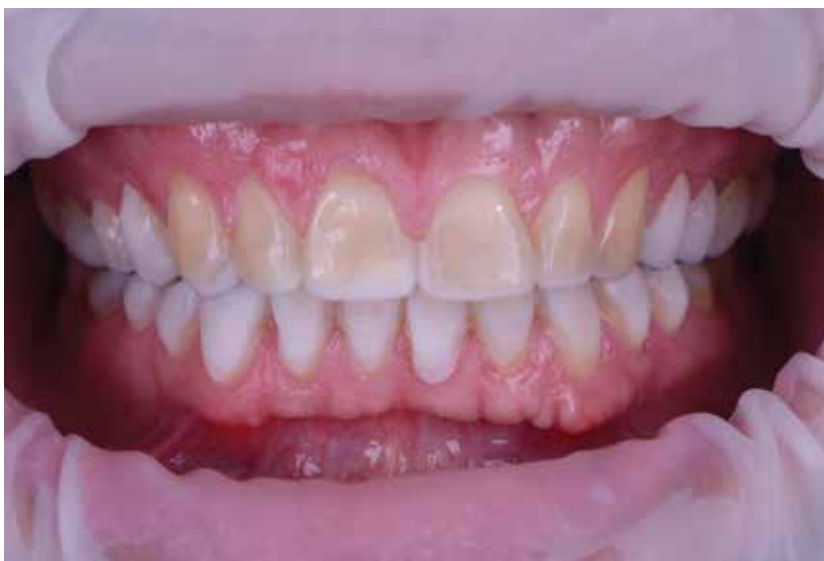



**Figure 6:** Recording the new bite.



**Figure 7:** Preparing the mock-up.



**Figure 8:** Functional mock-up.

The occlusion was tested in static and dynamic position using articulating paper. Static position was verified by the patient biting on the mock-up to check the contact points between the upper and lower cuspid fossa. Once the static position was verified, the dynamic position (i.e., mastication) was tested: The patient chewed on the right side of his mouth and the clinician verified the surface guidance on the molars, premolars, and canines. If the surface guidance is not equal, adjustments must be made. If guidance is present only on the canines, for example, the clinician has two possible courses for adjustment: Composite can be removed from the canines to match the premolars and molars, or composite can be added to the premolars and molars to create equal guidance with the canines.

The same verification process as described above was conducted on the patient's left side. Surface guidance was confirmed to be equal on all occlusal surfaces. Finally, the patient was asked to move his jaw laterally to verify group function, as well as in propulsion to verify guidance on the two central incisors. The authors prefer to work with group rather than canine function because it allows for a more effective mastication cycle. The more effective the mastication cycle, the less the masticator muscles need to work and therefore they become less worn. Everything was confirmed as being in equilibration. The position of the incisal edge was inspected, videos were made and photographs taken, and the patient was consulted to be sure he was satisfied with the outcome.

## Digital Planning and Esthetics

The esthetic study was done digitally (Digital Smile Design [DSD]; São Paulo, Brazil; and the SKYN Concept [São Paulo, Brazil]).<sup>10-14</sup> After the occlusal maxillary and mandibular mock-up was performed, we took photographs and made videos that enabled us to complete the esthetic study. Because the patient had, as is common, presented with a slight asymmetry, we decided to use the vertical glabella-philtrum line as a reference line. The DSD protocol was followed and we determined the ideal length, width, and position of the future teeth (Fig 9).<sup>10,11</sup> No gingival retouching was necessary.

## Recreating Natural Morphology

The DSD tool supplied the ideal proportions for the future restorations, the surfaces and shapes of which were selected from models of natural teeth. The SKYN concept creates a thin composite shell on natural teeth to copy the form and surface texture, then uses this shell to perform the mock-up. (Fig 10)<sup>12-14</sup> Once the mock-up is validated the laboratory can begin to emulate nature. A silicone impression of the model teeth's buccal surfaces was taken.

A thin layer of composite was added and photopolymerized in the silicone impression. The composite shell was then carefully removed, positioned in the patient's mouth, and fixed onto the tooth with composite. During the creation of this SKYN mock-up, it was important to pay attention to the emergence profile, incisal edge position, and gingival zenith. After this mock-up was done, a video was made to validate the esthetics of the patient's future smile.

## Definitive Restorations

After the patient had worn the mock-up for the prescribed two months, it was time to fabricate the definitive restorations. CAD/CAM (CEREC, Sirona Dental Systems; Charlotte, NC) was utilized to copy the exact morphology of the teeth. Indeed, one of the laboratory technician's most challenging tasks is to copy the shape of the teeth to conserve anterior guidance and the occlusal morphology when advancing from the temporary to the final restorations. With CAD/CAM, we were able to exactly copy the mock-ups the patient had worn and validated.<sup>14</sup>

The first impression taken was the mock-up. The next step was to prepare the teeth as minimally as possible through the mock-up to eliminate the least amount of dental tissue. The aesthetic pre-evaluative temporary (APT)<sup>15-17</sup> technique was selected for minimal selective reduction (Fig 11). Because the teeth were very abraded, we could have worked with ceramic elements such as crowns, but without preparation of contact points so as to cause the least damage possible and to conserve a maximum of enamel. This would involve connected double veneers where the incisal edge was involved. The amalgams, infiltrated composites, and old crowns in the back of the patient's mouth were removed. Once the preparations were perfectly polished and the immediate dentin sealing performed,<sup>18</sup> digital impressions were taken, along with a conventional PVS impression to create the plaster study model for the final restorations (Figs 12-14).

---

A transcutaneous electrical nerve stimulation (TENS) session was scheduled to determine the new occlusion.

---

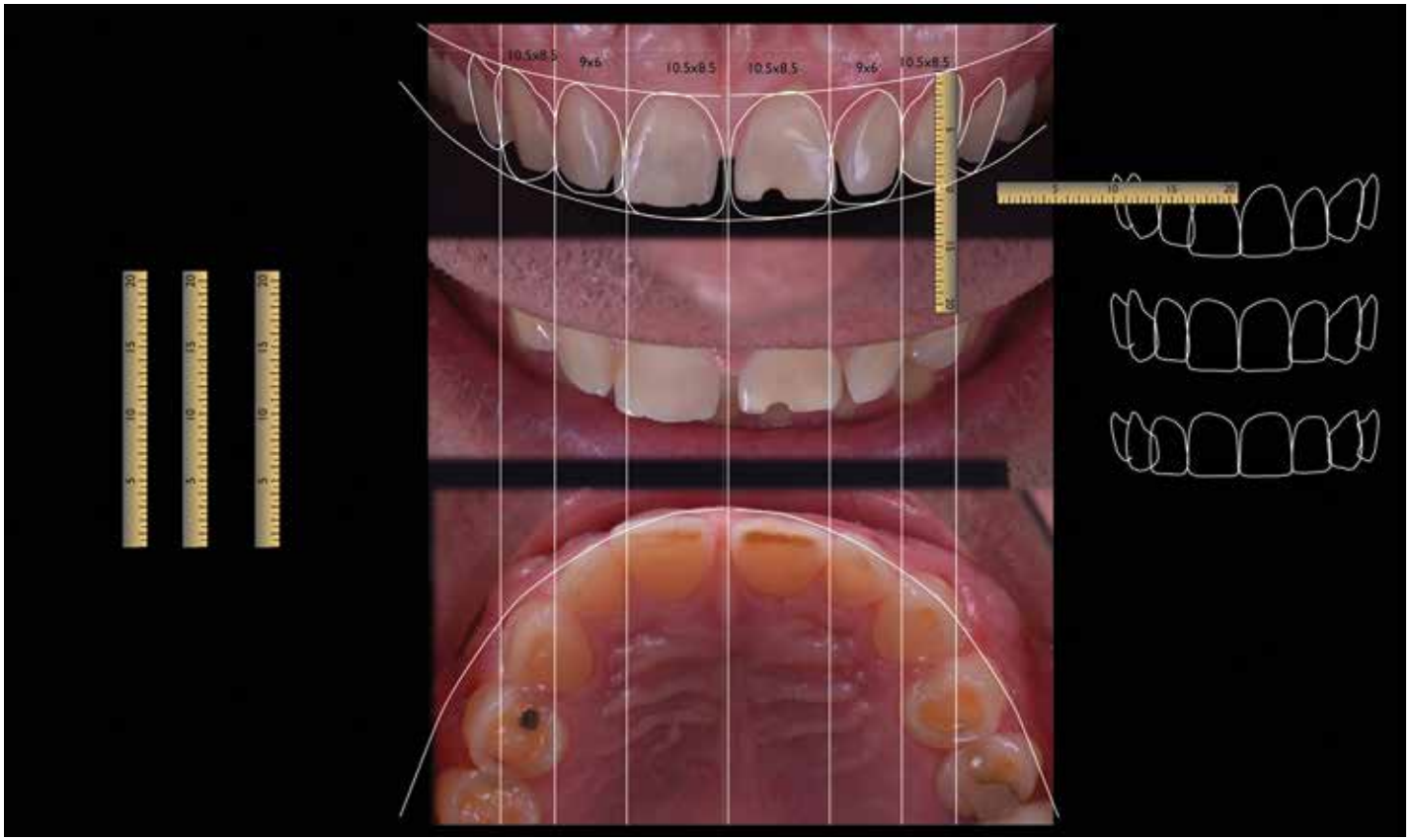


Figure 9: DSD study.

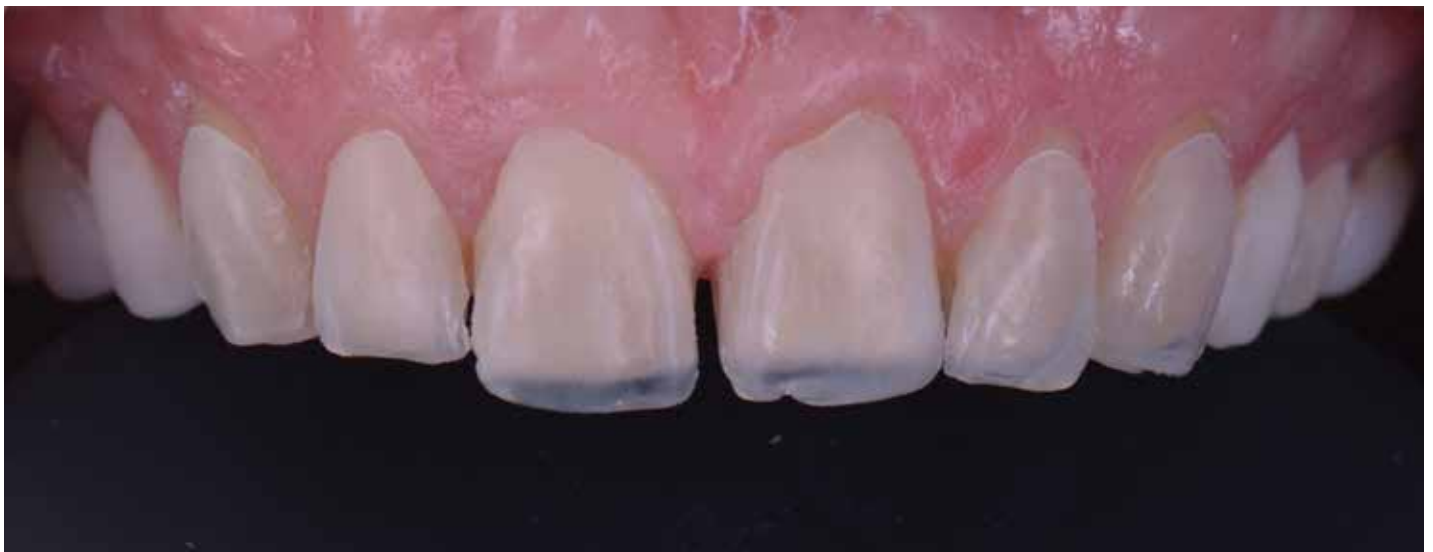
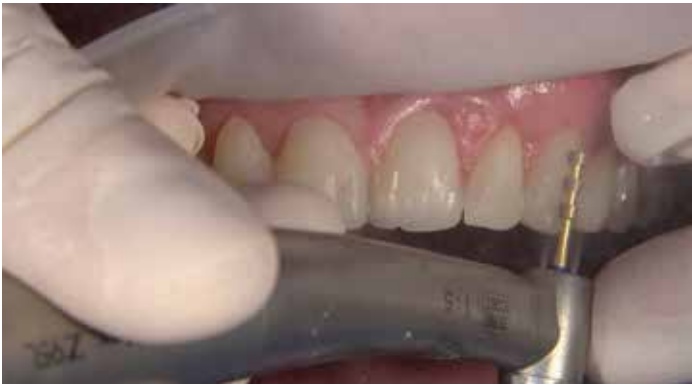
Figure 10: Skyn mock-up.

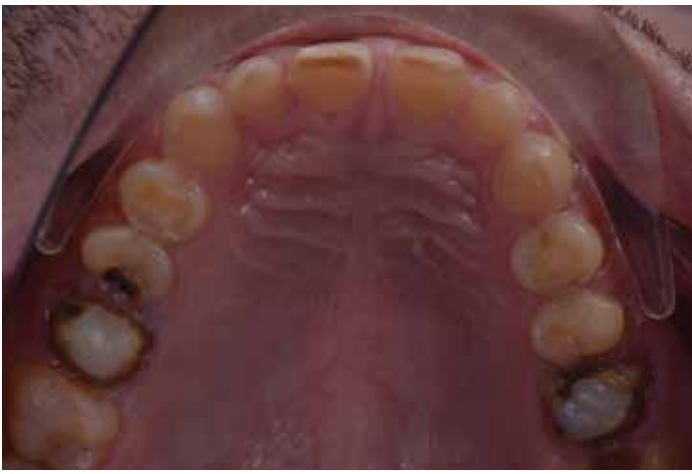



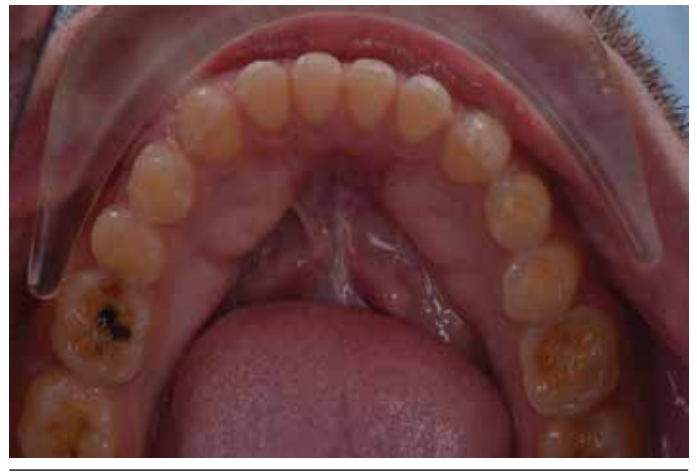**Figure 11:** Preparation with the APT technique.



**Figure 12:** Preparation of the anteriors.



**Figure 13:** Preparation of the upper jaw.



**Figure 14:** Preparation of the lower jaw.

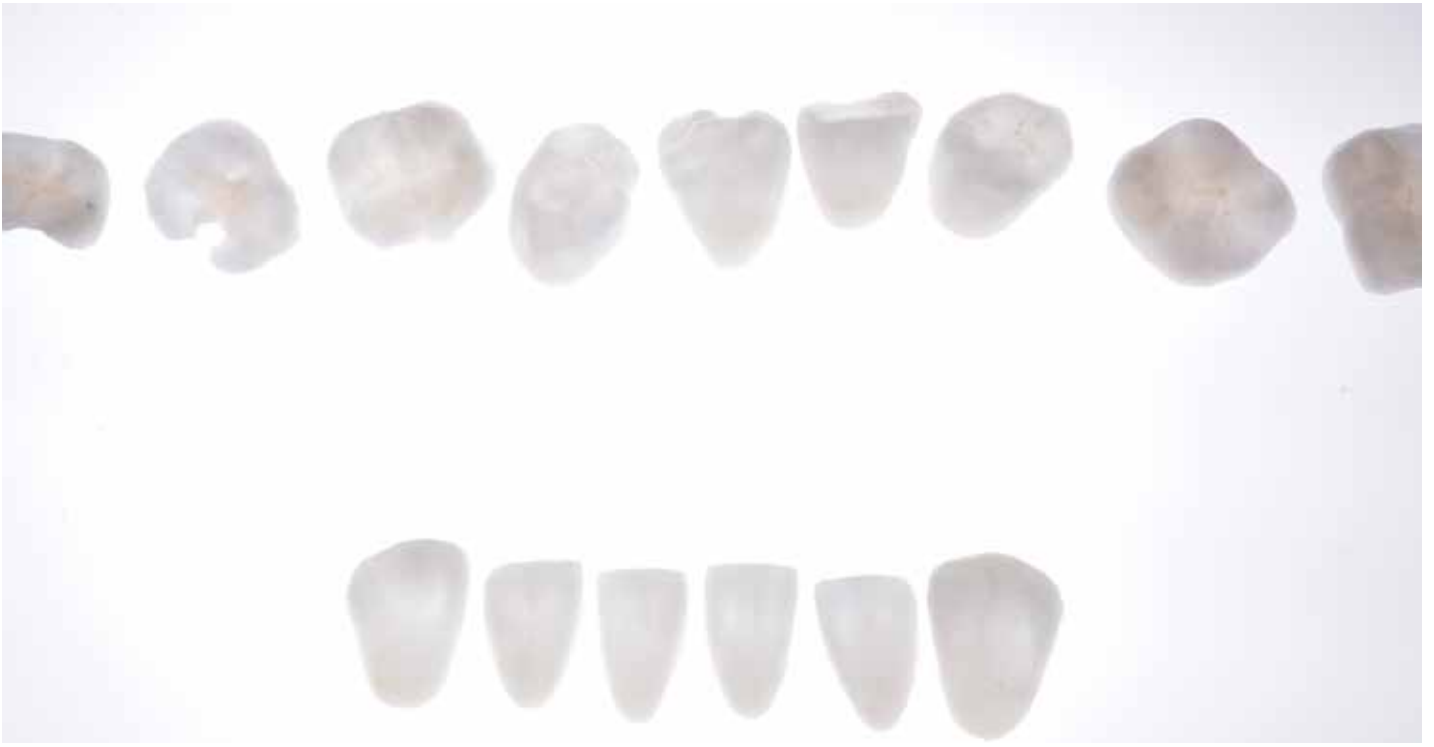### Creating the Prosthesis

The final restorations were created starting from the two digital impressions. The cervical limits were marked on the impression of the preparations. Next, the CEREC software matched the two impressions by subtraction and indicated the shape of the restorations to be milled. These restorations were an exact morphological copy of the mock-up the patient had worn. If the work is done section by section, the computer can match the impressions more easily. All the restorations were milled using leucite-reinforced glass-ceramic blocks (IPS Empress CAD Multi BL3, Ivoclar Vivadent; Amherst, NY) (Fig 15).<sup>19</sup> Each restoration could then be adjusted on plaster models if necessary. After milling, the restorations were stained using a three-dimensional (3D) staining technique that requires a specific sequence to create 3D optical illusions.

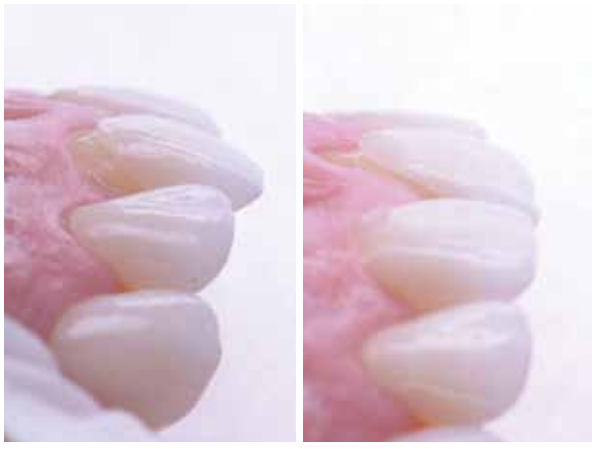### Bonding

A classic bonding protocol was followed. First, all ceramic elements were tried-in separately for validation and adjustment, then all together to check the contact points (Figs 16 & 17). The rubber dam was then placed on the maxillary. The intrados of the ceramic elements were prepared with 9.5% hydrofluoric acid for 60 seconds, rinsed well, and dried (Figs 18 & 19). A layer of saline was applied for 60 seconds then dried and heated.<sup>20</sup>

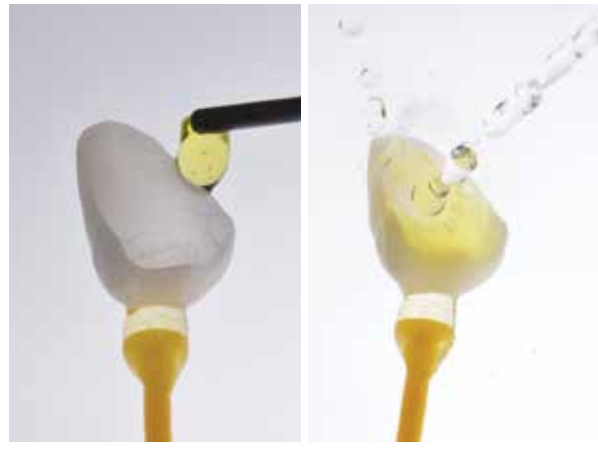A solution of 37% phosphoric acid was applied for 30 seconds on the enamel and 10 seconds on the dentin, after which the surfaces were rinsed, dried, and the adhesive was applied (Fig 20). The two central incisors were bonded first with light-cured resin cement. Excess material was eliminated (Fig 21) and final photopolymerization was performed with glycerin. Then the lateral incisors, canines, molars, and premolars were bonded. The mandibular restorations were bonded in the same manner. The occlusion was verified in static position with cusp fossa contact, and laterality, propulsion, and mastication were all checked. Final images can be seen in Figures 22 through 27.



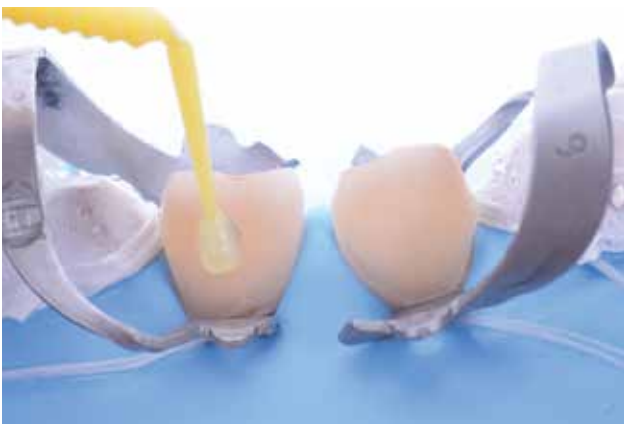**Figure 15:** Milled restorations.



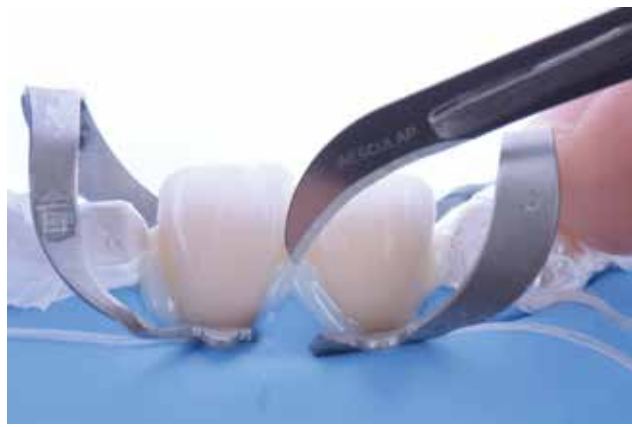**Figures 16 & 17:** Try-in.



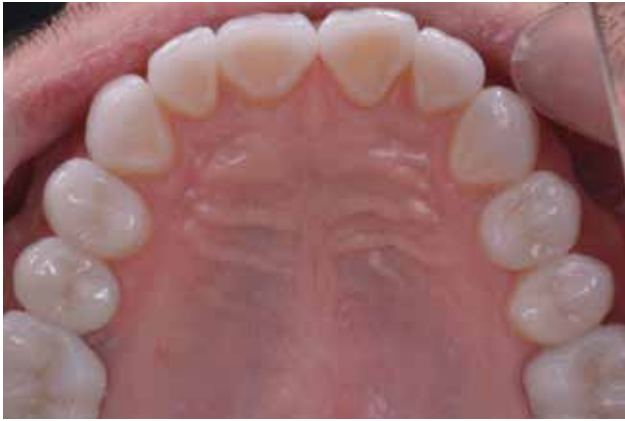**Figures 18 & 19:** Etching and rinsing a portion of the restoration.



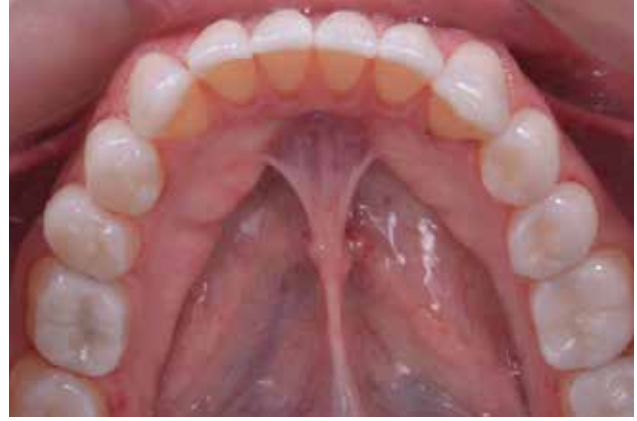**Figure 20:** Applying adhesive.



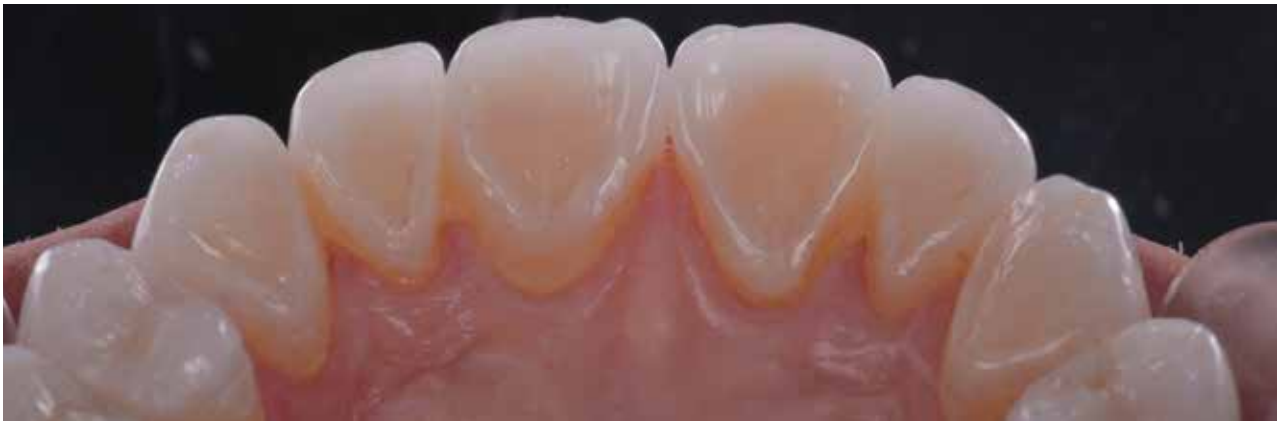**Figure 21:** Eliminating excess material with a blade.



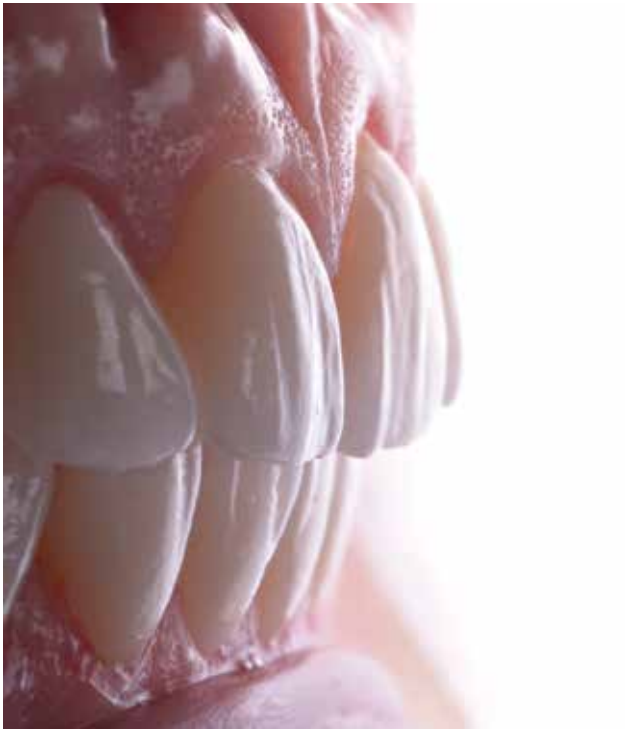**Figure 22:** Final upper jaw.



**Figure 23:** Final lower jaw.



**Figure 24:** Palatal face.

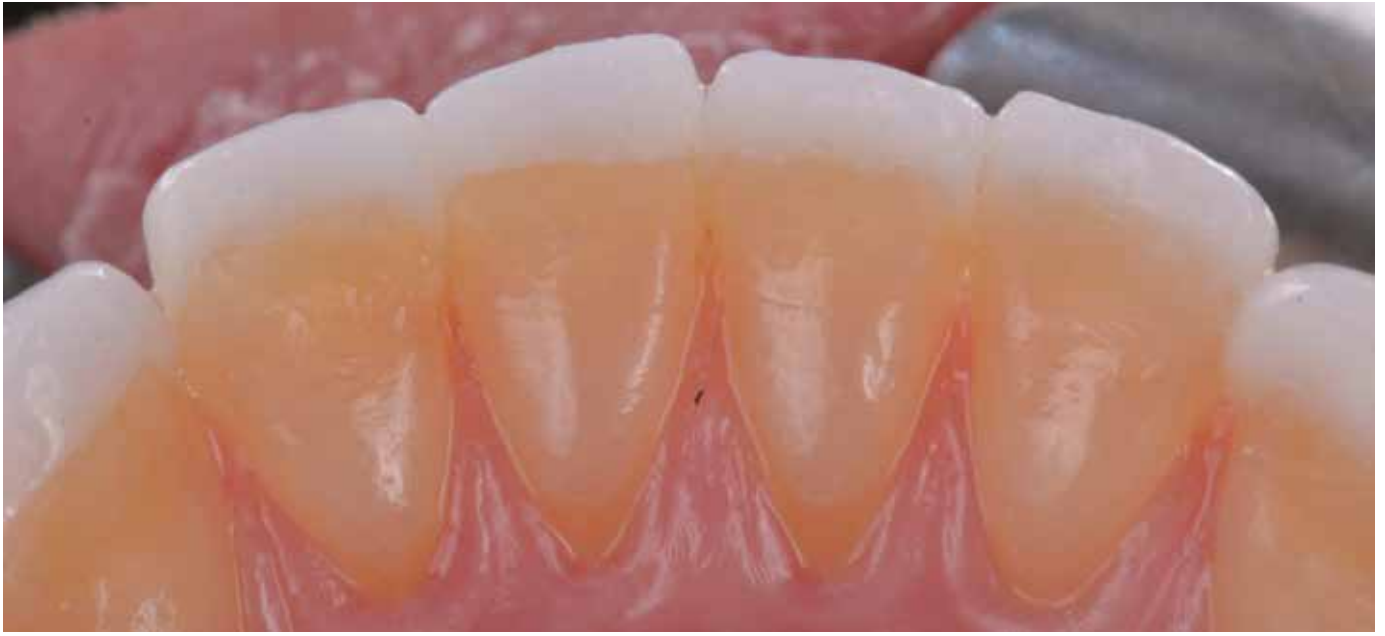

**Figure 25:** Texture.

\_\_\_\_\_

The teeth were not prepared in any way.

\_\_\_\_\_



**Figure 26:** Adaptation of the veneers.



**Figure 27:** Final new smile.



## Summary

The three most important aspects of a full-mouth rehabilitation are function, esthetics, and patient satisfaction. Treatment that utilizes physiologic occlusion (with muscle relaxation and TENS), a natural morphology, a complete mock-up to validate all elements, a digital impression system, and CAD/CAM appears very promising. Our treatments must be esthetic, functional, and minimally invasive, but also, and most importantly, biologically sound.

## References

1. Johansson AK, Omar R, Carlsson GE, Johansson A. Dental erosion and its growing importance in clinical practice: from past to present. *Int J Dent*. 2012;2012:632907.
2. Almeida e Silva JS, Baratieri LN, Araujo E, Widmer N. Dental erosion: understanding this pervasive condition. *J Esthet Restor Dent*. 2011 Aug;23(4):205-16.
3. Lussi A, Jaeggi T. Erosion—diagnosis and risk factors. *Clin Oral Investig*. 2008 Mar;12(Suppl 1):S-13.
4. de Andrade OS, Borges GA, Stefani A, Fujii F, Battistella P. A step-by-step ultraconservative esthetic rehabilitation using lithium disilicate ceramic. *QDT* 2010. Hanover Park (IL): Quintessence Pub.; 2010. p.114-131.
5. de Andrade OS, Kina S, Hirata R. Concepts for an ultraconservative approach to indirect anterior restorations. *QDT* 2011. Hanover Park (IL): Quintessence Pub.; 2011. p. 103-19.
6. de Andrade OS, Romanini JC, Hirata R. Ultimate ceramic veneers: a laboratory-guided ultraconservative preparation concept for maximum enamel preservation. *QDT* 2012. Hanover Park (IL): Quintessence Pub.; 2012. p. 29-43.
7. Kasat V, Gupta A, Ladda R, Kathariya M, Saluja H, Farroqui AA. Transcutaneous electric nerve stimulation (TENS) in dentistry – a review. *J Clin Exp Dent*. 2014 Dec;6(5):e562-8.
8. Monaco A, Sgolastra F, Ciarrocchi I, Cattaneo R. Effects of transcutaneous electrical nervous stimulation on electromyographic and kinesiographic activity of patients with temporomandibular disorders: a placebo-controlled study. *J Electromyogr Kinesiol*. 2012 Jun;22(3):463-8.
9. Yurchenko M, Hubáľková H, Klepáček [Lynette – pls put a diacritic wedge mark/caron over the c] I, Machon [pls put a diacritic wedge mark/caron over the n] V, Mazánek J. The neuromuscular approach towards interdisciplinary cooperation in medicine. *Int Dent J*. 2014 Feb;64(1):12-9.
10. Coachman C, Van Dooren E, Gürel G, Landsberg CJ, Calamita MA, Bichacho N. Smile design: from digital treatment planning to clinical reality. In: Cohen M, editor. *Interdisciplinary treatment planning*. Hanover Park (IL): Quintessence Pub.; 2012. p. 119-74.
11. Magne P, Belser U. Bonded porcelain restorations in the anterior dentition: a biomimetic approach. Hanover Park (IL): Quintessence Pub.; 2002.
12. Kano P, Xavier C, Ferencz JL, Van Dooren E, Silva NFR. Anatomical shell technique: an approach to improve the esthetic predictability of CAD-CAM restorations. *QDT* 2013. Hanover Park (IL): Quintessence Pub.; 2013. p. 38-58.
13. Kano P, Baratieri LN, Decurcio R, Duarte S, Saito P, Ferenca J, Silva NFR. The anatomical shell technique: mimicking nature. *QDT* 2014. Hanover Park (IL): Quintessence Pub.; 2014. p. 94-112.
14. Cofar F, Gaillard C, Popp I, Hue C. Skyn concept: a digital workflow for full-mouth rehabilitation. *QDT* 2016. Hanover Park (IL): Quintessence Pub.; p. 47-56.
15. Gürel G. The science and art of porcelain laminate veneers. London: Quintessence Pub.; 2003. Chapter 7, *Atlas of porcelain veneers*; p. 231-344.
16. Edelhoff D, Sorenson JA. Tooth structure removal associated with various preparation designs for anterior teeth. *J Prosthet Dent*. 2002 May;87(5):503-9.
17. Gürel G, Morimoto S, Calamita MA, Coachman C, Sesma N. Clinical performance of porcelain laminate veneers: outcomes of the aesthetic pre-evaluative temporary (APT) technique. *Int J Periodontics Restorative Dent*. 2012 Dec;32(6):625-35.
18. Magne P. IDS: Immediate dentin sealing (IDS) for tooth preparations. *J Adhes Dent*. 2014 Dec;16(6):594.
19. Gürel G, Yerusalmi BM, Shayder A. Monolithic CAD/CAM porcelain laminate veneers with external staining. *QDT* 2013. Hanover Park (IL): Quintessence Pub.; 2013. p. 174-82.
20. Phark JH, Sartori N, Duarte S. Bonding to silica-based glass-ceramics: a review of current techniques and novel self-etching ceramic primers. In: Duarte S, editor. *QDT* 2016. Hanover Park (IL): Quintessence Pub.; 2016. p. 26-36. **JCD**

---

Surface guidance was confirmed to be equal on all occlusal surfaces.

---



Dr. Gaillard is a co-founder of Global Advanced Dentistry in Bordeaux, France, where he maintains a private practice. He can be contacted at [doc.gaillard@gmail.com](mailto:doc.gaillard@gmail.com)



Dr. Cofar is an instructor at Dentcof Dental Implants & Aesthetics Center in Timisoara, Romania. He can be contacted at [florin.cofar@dentcof.ro](mailto:florin.cofar@dentcof.ro)



Ms. Popp is an instructor at Dentcof Dental Implants & Aesthetics Center in Timisoara, Romania. She can be contacted at [ioana.popp@dentcof.ro](mailto:ioana.popp@dentcof.ro)



Mr. Bellamy is a co-founder and instructor at Global Advanced Dentistry, in Bordeaux, France. He can be contacted at [j.bellamy@globalesthetics.com](mailto:j.bellamy@globalesthetics.com)



Mr. Hue is a co-founder and instructor at Global Advanced Dentistry, in Bordeaux, France. He can be contacted at [christophe-hue@orange.fr](mailto:christophe-hue@orange.fr)

Disclosures: The authors did not report any disclosures.

